Human & Veterinary Medicine
International Journal of the Bioflux Society HVM

OPEN ACCESS
Case Report

# Orthodontic treatment in periodontally affected patients: a case report

[1]Dana Festila, [2]Rares Roman, [1]Mircea Ghergie
[1] Department of Orthodontics, "Iuliu Hatieganu" University of Medicine and Pharmacy, Cluj-Napoca, Romania; [2] Department of Maxillo-Facial Surgery, "Iuliu Hatieganu" University of Medicine and Pharmacy, Cluj-Napoca, Romania.

**Abstract.** This case report demonstrates the orthodontic treatment for a periodontal affected 35-year-old woman presenting with a Class II malocclusion with moderate maxillary anterior crowding and severe mandibular crowding, 7 mm overjet, 3.3 mm overbite and moderate to severe bone loss as the main characteristics of the periodontal disease. The orthodontic treatment included maxillary affected lateral incisors extraction even if the extraction of a periodontal affected tooth is controversial nowadays and lower first premolars. Active orthodontic treatment was completed in 21 months. The treatment outcomes, including the periodontal condition, were stable after active orthodontic treatment. Problems of the comprehensive orthodontic therapy, treatment protocol and benefits of the interdisciplinary treatment are presented.

**Key Words:** periodontal disease, skeletal anchorage, interdisciplinary treatment.



**Corresponding Author:** D. Festila, e-mail: dana.festila@gmail.com

## Introduction

When periodontal disease has already produced significant destruction of supporting tissue and secondary occlusal trauma is a complicating factor, orthodontic treatment may possibly serve as another mode of treatment to re-establish the correct occlusal plan and alter bony deformities. Extraction of periodontally affected teeth is controversial and new periodontal therapeutic approaches allow their preservation. However, in the present case, to gain space, for a better case prognosis, shorter treatment time and reduced treatment costs, we preferred to extract periodontally affected lateral incisors instead of first premolars.

## Case History

A 35-year-old woman presented with the chief complaints of an unaesthetic appearance of the upper incisors. She had a long face, contracted soft chin, fallen apart and protrusive lips, exposed and crowded upper incisors and convex profile (Figure 1).

Figure 1. Initial facial aspect

The dental arches were narrow with a lack of space in the frontal region that caused the incisor's protrusion. The occlusal relationships were class I in left molar and canines on both sides and class III in molar on the right side with a slight lower midline deviation to the right and cross-bite tendency more pronounced on the left side (Figure 2).

Figure 2. Initial dental arches and occlusion

Cast analysis showed an arch-length discrepancy of 3 mm in the upper arch and 6.8 mm in the lower one, 7 mm overjet, 3.3 mm overbite (Figure 3).
The radiographs revealed moderate to severe bone loss especially in the upper lateral incisors (Figure 4).

Figure 3. Initial dental casts

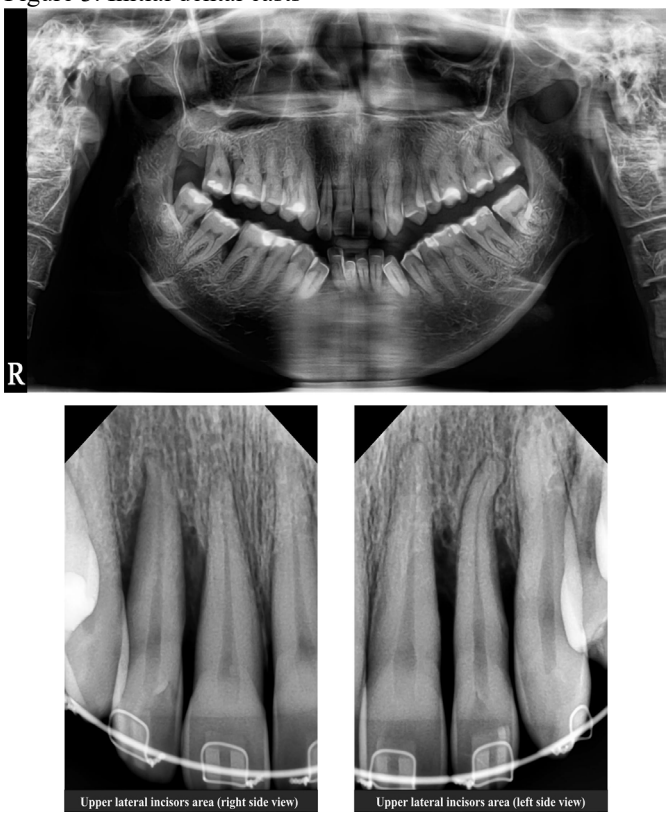


Figure 4. Initial radiological aspect

She was skeletal class II (SNA 81°, SNB 70°, AoBo 7 mm with a posterior mandible's rotation), slight protruded upper and lower incisors (I-NSe 109°, IMPA 94°) (Figure 5).

Orthodontic treatment objectives were to relieve crowding, to align the teeth, to correct midline discrepancy, to obtain a normal overbite and to improve the facial aesthetic. We believed extraction treatment was the best option because of the patient's long face, convex profile and the amount of space needed for teeth alignment. We decided to extract the upper lateral incisors due to their poor periodontal condition and the lower first premolars. We initiated the treatment in the upper arch. After leveling and alignment, we placed miniscrews between the first molar and second premolar bilaterally. As a substitute for

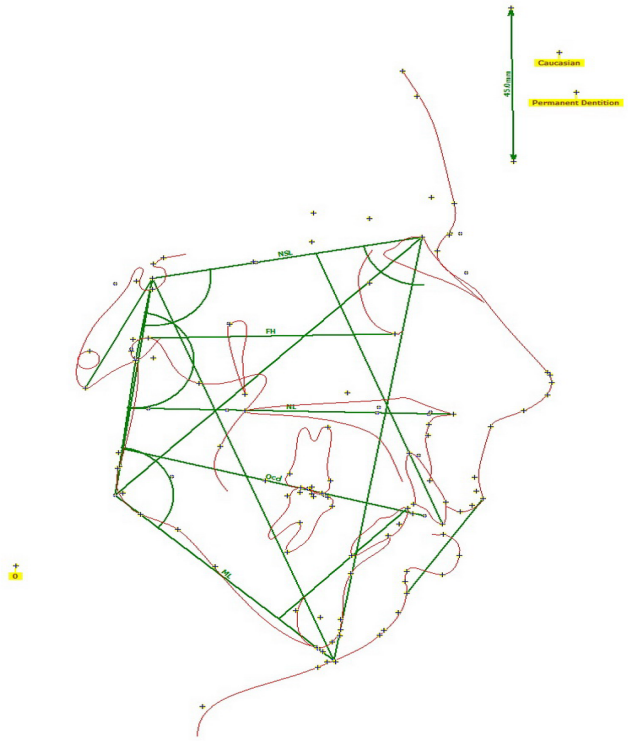


Figure 5. Initial cephalogram

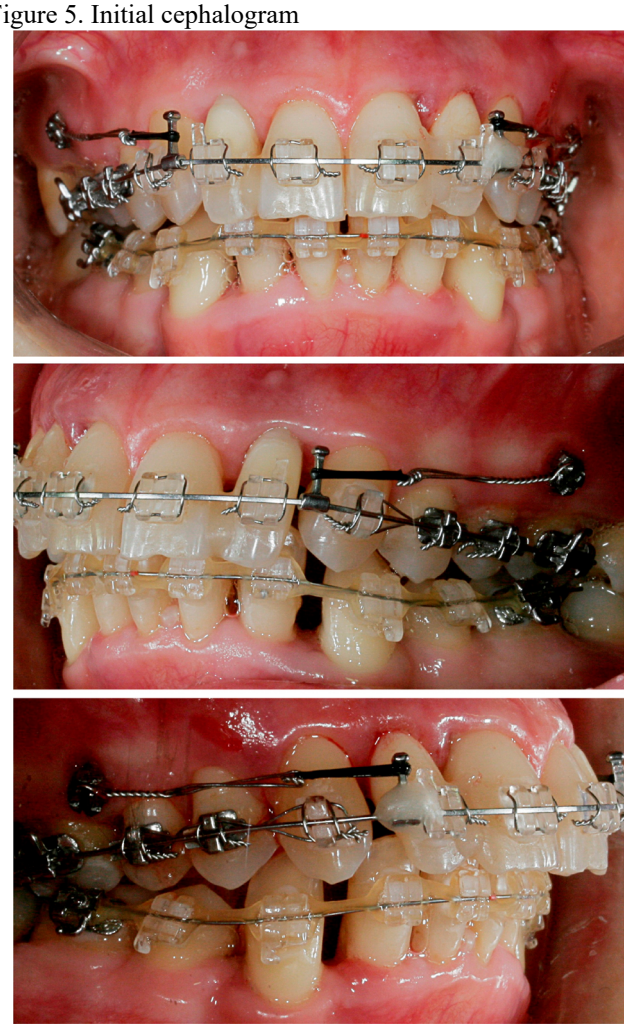

Figure 6. Retraction phase

extracted lateral incisors, we put acrylic crowns with brackets ligated to the arch and soldered by composite material to the adjacent central incisors. Tie-back ligatures were attached from miniscrews to hooks placed distal to the acrylic crowns. With every activation session we trimmed 2 mm from the distal part of the acrylic crowns to allow the central incisor's retraction. Canine's brackets were replaced by lateral incisors brackets going on with another short time of alignment (Figure 6).
The lower arch was bonded six months later and the canines were retracted with segmented arches. Total treatment time was one year and nine months. A good teeth alignment and occlusion were obtained, as well as a correct midline position and a pleasant smile (Figures 7, 8).

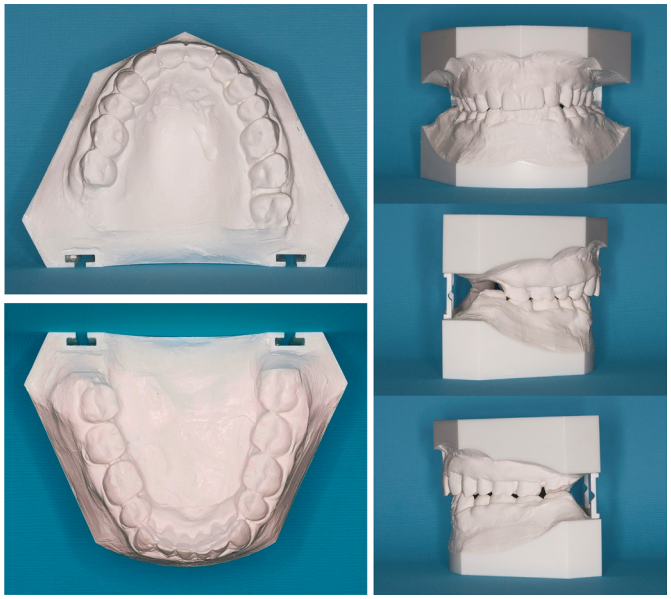

Figure 7. Final dental casts

Figure 8. Final facial aspect in repose and smile

We prescribed a wraparound retainer together with a first premolar-to-first premolar bonded one in the upper arch and canine-to-canine bonded retainer in the lower arch (Figure 9).
Panoramic radiograph was completed after the orthodontic treatment. No more bone loss occurred during or after the orthodontic treatment (Figure 10).
Orthodontic treatment was referred only for dental changes (bimaxilary retrusion, I-NSe 98°, IMPA 88°), not for skeletal (Figure 11).

Figure 9. Final dental arches and occlusion


Figure 10. Final radiological aspect

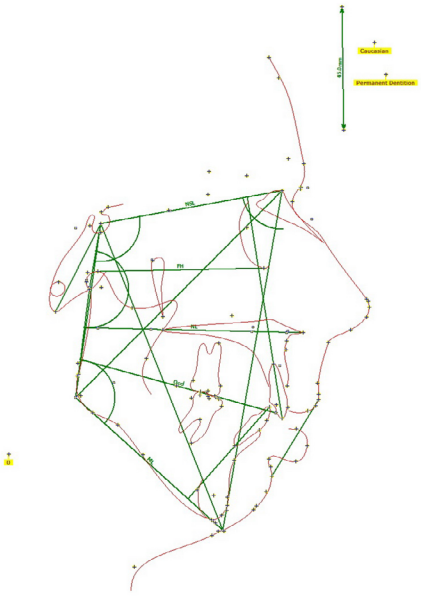

Figure 11. Final cephalogram

The patient was seen every six weeks for periodontal maintenance. She was then referred to a general dentist to reshape her upper canines and to a dental surgeon to extract the lower right wisdom tooth which interfered in propulsion with the upper right second molar (Figure 9).

## Discussion

An interdisciplinary periodontal-orthodontic treatment could be beneficial even in a case that seems hopeless, but these patients should be seen frequently for periodontal maintenance and minimal orthodontic forces should be applied. (Reichert et al 2011; Rotundo et al 2010) During orthodontic treatment, a strict oral hygiene program was applied, including oral hygiene control and professional tooth cleaning every six weeks. The therapeutic protocol in long face, biprotrusive cases is to extract four first premolars. Accentuated bone loss in the upper lateral incisors led us to do their extraction although in some opinions a reduction in vertical bone height is not a contraindication for orthodontic tooth movement. Moreover, regenerative therapy in hopeless teeth gives a suitable alternative to extraction of severely compromised teeth with intra-bony defects. (Leung et al 2008; Panwar et al 2014) An appropriate force system should be used to treat adult patients with periodontal disease like segmental arches and skeletal anchorage. (Panwar et al 2014) More recently, great emphasis has been placed on the miniscrew type of temporary anchorage devices, a viable alternative to achieve sufficient anchorage. Under these circumstances tooth movement is quite possible despite bone loss. (Lee et al 2009) Space closure in areas of major bone loss sometimes leads to an improvement in bone height and reconstructs the interproximal papillae. (Proffit 2007; Erkan et al 2007; Sorel et al 2010; Cardaropoli 2009)

In this case the panoramic radiograph shows that the periodontal condition remained under good control during and after treatment and the fill-in of alveolar bone in the area where the severely affected lateral incisors were extracted can be noted. Only between the lower right lateral incisor and the canine can be seen more pronounced bone resorption, maybe due to the destruction of the crestal bone and due to their roots being too spread apart instead of being more parallel.

The planning of retention and stability after orthodontic treatment requires greater consideration in periodontal compromised patients; permanent retention is often part of the treatment plan. A long-term lingual-bonded wire retainer was applied in the upper and lower arch.

In conclusion, the interdisciplinary treatment approach that involved nonsurgical periodontal therapy, orthodontic tooth movement with the use of skeletal anchorage and final restorative treatment resulted in significant functional, aesthetic and periodontal improvements.

## References


Cardaropoli D. Orthodontics for the adult periodontal patient: first or second choice treatment? Prog Orthod 2009;10:88-96.

Erkan M, Pikdoken L, Usumez S. Gingival response to mandibular incisor intrusion. Am J Orthod Dentofacial Orthop 2007;132:143.e9-13.

Lee TC, Leung MT, Wong RW, Rabie AB. Versatility of skeletal anchorage in orthodontics. World J Orhod 2008;9:221-32.

Leung MT, Lee TC, Rabie AB, Wong RW. Use of miniscrews and miniplates in orthodontics. J Oral Maxillofac Surg 2008;66:1461-6.

Panwar M, Jayan B, Arora V, Singh S. Orthodontic management of dentition in patients with periodontally compromised dentition. J Indian Soc Periodontol 2014;18:200-4.

Proffit WR. Special considerations in treatment for adults. In: Proffit WR, Fields HW, Sarver DM, editors. Contemporary orthodontics. St. Louis: Mosby Elsevier; 2007. pp. 662.

Reichert C, Hagner M, Jepsen S, Jäger A. Interfaces between orthodontic and periodontal treatment: their current status. J Orofac Orthop 2011;72:165-86.

Rotundo R, Nieri M, Iachetti G, Mervelt J, Cairo F, Baccetti T, et al. Orthodontic treatment of periodontal defects: a systematic review. Prog Orthod 2010;11:41-4.

Sorel O, Glez D, Hourdin S. Contribution of orthodontics in treatment planning patients with reduced periodontium. Orthod Fr 2010;81:27-32.


## Authors


Dana Festila, Department of Orthodontics, "Iuliu Hatieganu" University of Medicine and Pharmacy, 33 Calea Motilor street, 400001, Cluj-Napoca, Cluj, Romania, EU, email: dana.festila@gmail.com

Rares Roman, Department of Maxillo-Facial Surgery,"Iuliu Hatieganu" University of Medicine and Pharmacy, 33 Calea Motilor street, 400001, Cluj-Napoca, Cluj, Romania, EU, email: raresroman@yahoo.com

Mircea Ghergie, Department of Orthodontics, "Iuliu Hatieganu" University of Medicine and Pharmacy, 33 Calea Motilor street, 400001, Cluj-Napoca, Cluj, Romania, EU, email: mirceaghergie@yahoo.com



| | |
|---|---|
| **Citation** | Festila D, Roman R, Ghergie M. Orthodontic treatment in periodontally affected patients: a case report. HVM Bioflux 2016;8(1):1-4. |
| **Editor** | Ştefan C. Vesa |
| **Received** | 2 December 2015 |
| **Accepted** | 17 December 2015 |
| **Published Online** | 21 December 2015 |
| **Funding** | None reported |
| **Conflicts/ Competing Interests** | None reported |