

# The role of laparoscopic approach in reducing complications of peritoneal dialysis

<sup>1</sup>Anca Manta, <sup>1</sup>Cristian I. M. Iorga, <sup>1</sup>Victor Strimbu, <sup>2</sup>Florian Popa

<sup>1</sup> Department of General Surgery, Clinical Hospital of Nephrology “Dr. Carol Davila”, Bucuresti, Romania; <sup>2</sup> Department of General Surgery, Clinical Emergency Hospital “Sf. Pantelimon”, Bucuresti, Romania.

**Abstract.** Introduction: Peritoneal dialysis is one of the treatment methods for patients with end-stage CKD. In Romania there are about 900 patients on peritoneal dialysis, with 150 new patients with dialysis annually. The key element in the success of this procedure is the peritoneal dialysis catheter insertion. Material and method: The retrospective study carried out during the period 2011-2014, included patients with removal and insertion of peritoneal dialysis catheters (performed in both the open and laparoscopic manner) within the Clinical Hospital of Nephrology “Dr. Carol Davila” Bucharest, General Surgery Department. Results: Of all the patients with peritoneal dialysis catheter insertion, there were 3 cases of postoperative complications: an immediate one, with bleeding at the level of the parietal tunnel, and two cases that were late: a patient with the mobilization of the dialysis catheter, and in the second case the greater omentum was wrapping around the catheter. In patients with peritoneal dialysis catheters removal, the causes were: repeated peritonitis, peritoneopleural fistula, accidental cutting of the catheter, complications of encapsulating peritoneal sclerosis, catheter malfunction. Conclusions: The laparoscopic approach has many advantages, both common to any intervention, and specific to this procedure. Complications in case of this type of approach are less than in open surgery.

**Key Words:** peritoneal dialysis, laparoscopic approach, mechanical and infectious complications.

**Copyright:** This is an open-access article distributed under the terms of the Creative Commons Attribution License, which permits unrestricted use, distribution, and reproduction in any medium, provided the original author and source are credited.

**Corresponding Author:** A. Manta, email: anca\_manta81@yahoo.com

## Introduction

Chronic kidney disease is a major public health problem due to the increasing number of patients with this disease registered in our country, which leads to significant morbidity and mortality. In our country there were 11,176 patients with CKD on December 31st, 2013, of which 854 patients were undergoing peritoneal dialysis, representing a rate of 7.64% (according to the Romanian Renal Registry).

The therapy of patients with end-stage CKD is complex and, currently, three therapeutic procedures are used with the same result: hemodialysis, peritoneal dialysis and kidney transplantation, but it is to mention that access to transplantation is very low. Although there is no consensus on this matter, and the percentage of patients with peritoneal dialysis in our country is on a downward trend (according to the Romanian Renal Registry, incidence of patients with peritoneal dialysis was of 221 in 2011, 170 in 2012 and 155 on December 31st, 2013), peritoneal dialysis should be the first therapeutic option in diagnosed patients, and also an alternative treatment for the patients who have already received hemodialysis and who have exhausted vascular bed (Wankowitz 2003).

Peritoneal dialysis is a process introduced by Popovich and Moncrief in 1976, with many subsequent adjustments (Mutter et al 1994; Pantea et al 2008; Popovich 1976). There are currently two ways of carrying out peritoneal dialysis: CAPD

(continuous ambulatory peritoneal dialysis) and APD (Automated Peritoneal Dialysis).

Regardless of the method of performing peritoneal dialysis, the main step is the peritoneal dialysis catheter insertion. There are several ways: the laparotomic approach, the laparoscopic approach, and, in carefully selected cases, Seldinger percutaneous approach and the peritoneoscopic approach (Crabtree et al 2009; Crabtree et al 2000; Pantea et al 2008; Wang et al 1999).

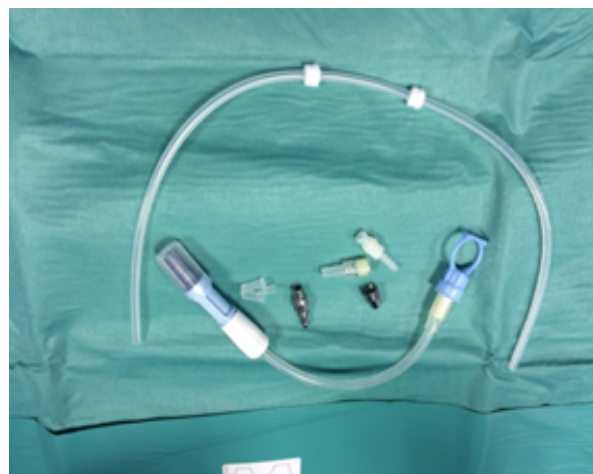

Figure 1. Peritoneal dialysis catheter (components)

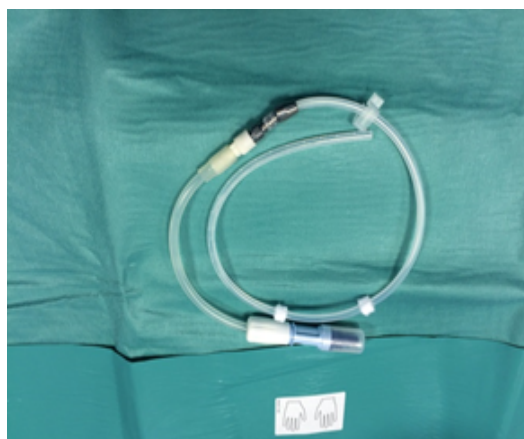

Figure 2. Peritoneal dialysis catheter(mounted)

Regardless of the used approach, the catheter insertion process is encumbered by numerous surgical complications that could be early or late (Patrascu et al 2008).

Data from the literature present early complications: bleeding, hollow organ perforation, wrong positioning of the catheter followed by its incorrect function, fluid leakage along the catheter (Checherita et al 2009; Patrascu et al 2008; Mital et al 2004). Late complications are also divided into: mechanical and infectious. We mention the following from the mechanical ones: catheter obstruction and mobilization (intraperitoneal segment) with or without obstruction, with or without subcutaneous cuff exteriorization, the occurrence of various types of fistulas (external peritoneal, peritoneo-intraparietal, peritoneo-pleural), pseudohydrocele, decubitus enteric fistula, hernias and eventrations (Patrascu et al 2008). A serious late complication of peritoneal dialysis, which appears closely related to the period of performing peritoneal dialysis, is the encapsulating peritoneal sclerosis. But infectious complications are the most frequent and severe ones, as they represent the main cause of failure of ultrafiltration and catheter removal. They are infections of the exteriorization breach, infections of the parietal tunnel, and peritonitis. We also encountered rare complications of peritoneal dialysis in our practice: pyloric stenosis and haemoperitoneum by effraction of a giant peritoneal cyst.

The purpose of the study is to follow the occurrence and frequency of complications of peritoneal dialysis in the case of celiotomic and laparoscopic approaches.

## Material and method

The study is retrospective by analyzing data obtained from medical records and operative protocols and it is carried out in the Clinical Hospital of Nephrology "Dr. Carol Davila" Bucharest, General Surgery Department, between January 2012 and August 2014. The study has two directions: the analysis of 22 cases of peritoneal dialysis catheter removal (of the complications that led to the failure of peritoneal dialysis and of the catheter removal, respectively) and the monitoring of 11 patients with end-stage chronic kidney disease who had peritoneal dialysis catheter placement by celiotomy or laparoscopy.

The patients provided a written informed consent to be treated and for the use of pictures.

Twenty-two patients were included in the group of patients with catheter removal, out of which 9 were women and 13 were men, with the average age of 60.86 years, the extremes being 25 years old and 83 years old.

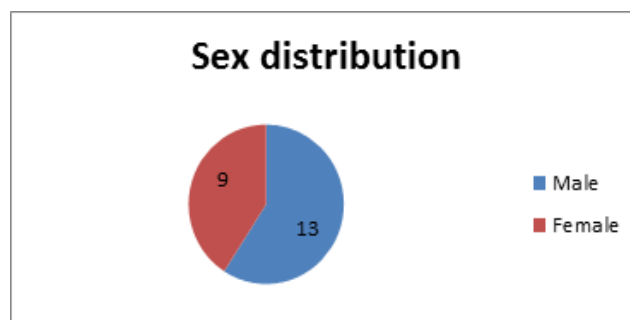


Figure 3. Sex distribution

The duration of peritoneal dialysis carried out up to the method's failure was of 35.59 months with a range between 1 month and 132 months.

The average operating time of catheter removal was 20 minutes, with limits between 15 and 35 minutes.

Eleven patients were included in the group of patients with catheter placement, of which 6 were women and 5 were men, with an average age of 53.2 years, with a range between 41 years and 71 years.

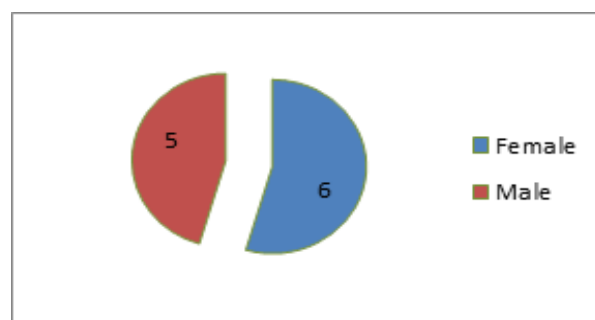


Figure 4. Sex distribution II

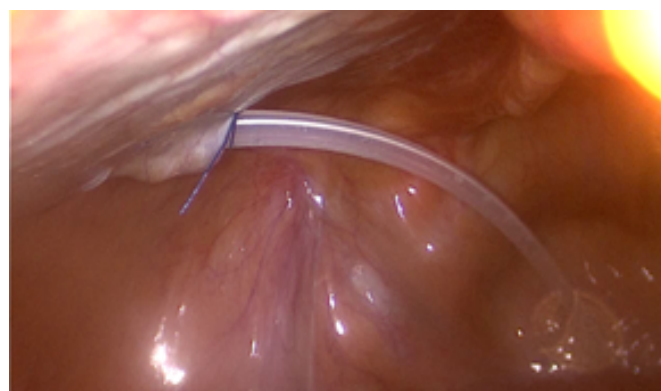


Figure 5. Fixation of the catheter at peritoneum

We performed placement of catheter by laparoscopy in 8 cases and by open classic method in 3 cases. We mention that the catheter was fixed to the peritoneum in all laparoscopic interventions. The average operating time for laparoscopic surgery was of 35 minutes, with limits between 30 and 45 minutes, and for the

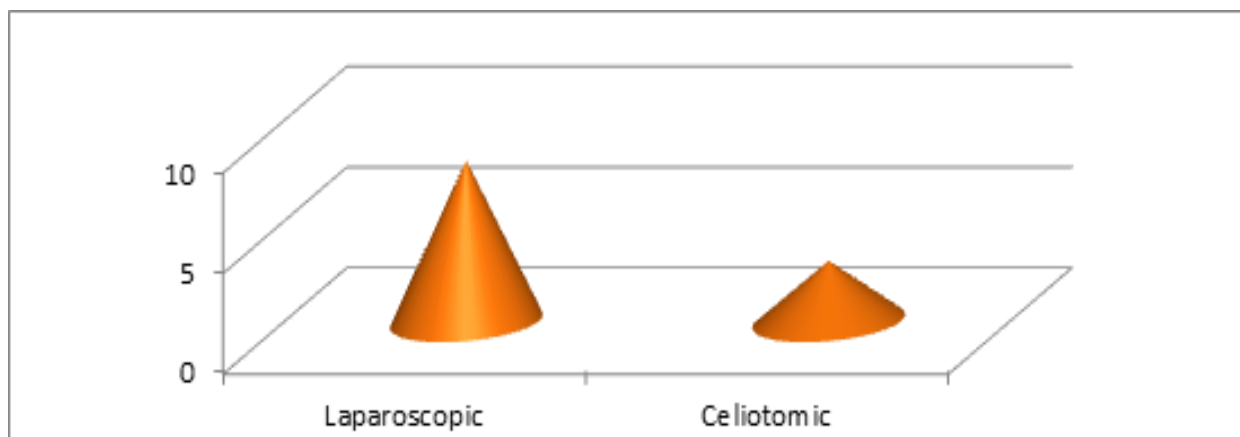


Figure 6. Distribution of the tipe of surgery

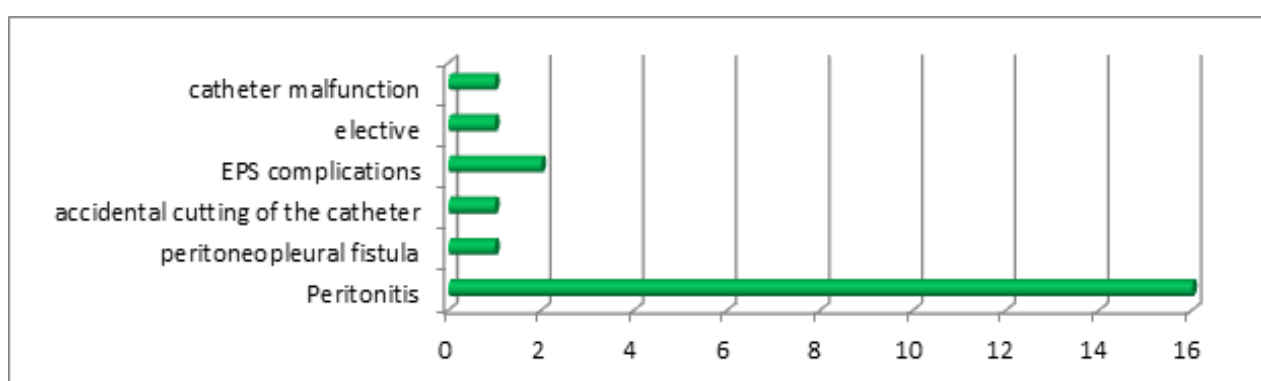


Figure 7. Causes which led to the removal of the catheter

classic intervention the time was of 20 minutes, with limits between 16 and 24 minutes.

## Results

The causes which led to the removal of the catheter were: repeated bacterial peritonitis (16 cases), peritoneopleural fistula (1 case), accidental cutting of the catheter (1 case), complications of encapsulating peritoneal sclerosis (2 cases: giant peritoneal cyst and pyloric stenosis), elective (1 case), catheter malfunction (1 case).

No complications were recorded after catheter removal.

An immediate postoperative complication was registered within the group with placement of peritoneal dialysis catheter, consisting of secondary hemorrhage of the tunnel that was treated conservatively.

Late complications were recorded in 2 patients: one patient presented catheter mobilization, which led to its malfunction, and there was one case of obliteration of the catheter with omentum, which was resolved without its resection. Both cases required laparoscopic reoperation; in the first situation there was a reoperation, the peritoneal cavity was explored and the catheter was repositioned; in the second situation there was a laparoscopic reoperation and catheter desobturation.

There has been a case of ultrafiltration failure, followed by removal of peritoneal dialysis catheter.

## Discussions

Peritoneal dialysis remains, together with hemodialysis, one of the main treatment methods for patients with chronic kidney disease, and access to transplantation is extremely low. The percentage of patients with chronic kidney disease who undergo peritoneal dialysis varies greatly worldwide, that is between 6% in Japan and 91% in Mexico. In Romania, the procedure was introduced in 1995 (Patrascu et al 2008).

The main advantages of peritoneal dialysis are the fact that the vascular bed is not used and the mobility offered to patient. Currently there are two methods of peritoneal dialysis: CAPD and APD, with the preponderance of cases treated by CAPD (Akman et al 2009).

For the method's success, the main problem that occurs is the peritoneal access, as complications that appear depend on it. An extremely important fact is represented by the experience of the operating team, rather than the type of catheter inserted (Rachandeeep et al 2009).

The objectives of a good peritoneal access are: the correct positioning of the catheter, as any mobilization or its obstruction are followed by the method's failure, a good sealing, so that fluid leakage along the catheter could be prevented, creating a parietal tunnel and an optimal exteriorization breach that, together with anti-infective prophylaxis, lowers postoperative complications. The exteriorization breach must be as small as

possible, adapted to the catheter size, and it is preferred to be left without being sutured (Figueiredo *et al* 2010).

Since the peritoneal dialysis appeared, various methods were imagined in order to achieve those objectives. So far, there is no consensus on the ideal method of approach for the placement of peritoneal dialysis catheter.

The first method used, which remains until today one of the main accessways, was the insertion of the catheter through laparotomy. The main advantage is that it is a simple method that could be feasible in most cases under local anesthesia. However, it presents many complications, especially an improper placement which, along with postoperative adhesions, will cause failure of the method (in some studies their percentage goes up to 22%) (Crabtree *et al* 2000; Crabtree *et al* 2009; Cronen *et al* 1985; Pantea *et al* 2008).

The next used techniques were the one by percutaneous placement of a catheter (Seldinger method) and the peritoneoscopic method that, although present a smaller number of such complications have a high percentage of hollow viscus perforations, in some studies the rate being of 2%(Pantea *et al* 2008).

The laparoscopic technique has many advantages, although it was not currently required to the placement of peritoneal catheters. It was initially introduced in 1990 to solve complications of open surgery. It was first used in 1995 in our country (Patrascu 2008). Among the advantages, we mention first the fact that direct visualization of the peritoneal cavity can be made. Thus, it can be directly evaluated the distance from the bottom of the breach to Douglas bag, with correct placement of the catheter in the bottom of Douglas bag; it gives us the possibility of fixing on sight the catheter to the peritoneum (ÖEünç *et al* 2003).

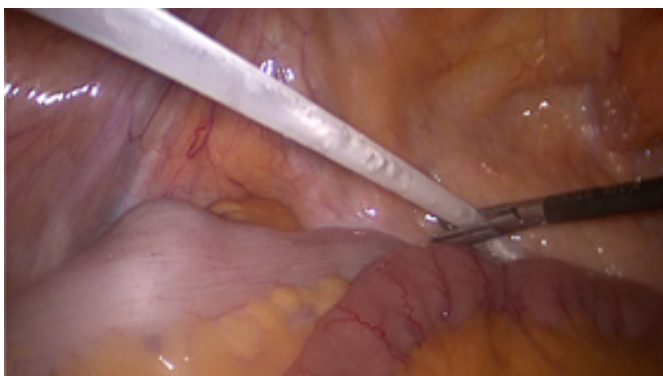


Figure 8. Place where the catheter is mounted (Douglas bag)

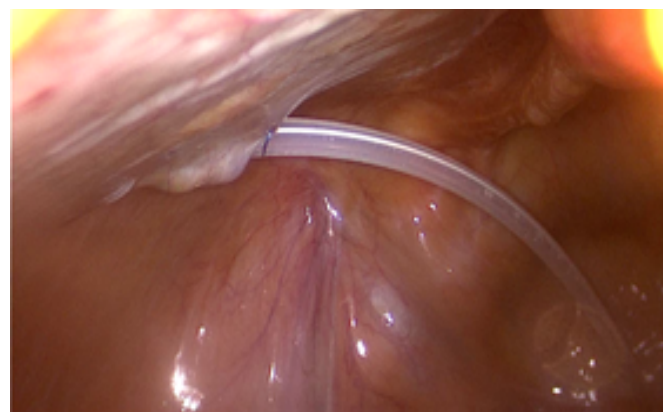


Figure 9. Direction of the catheter

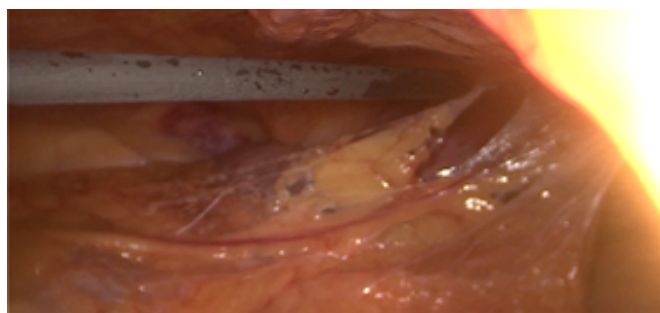


Figure 10. Dissection of adhesions

The presence of any adhesions requires their lysis to minimize unused space for dialysis.

Other advantages are the following: it allows other interventions while placing the catheter, it reduces the risk of inappropriate techniques followed by catheter malfunction, a lower total cost for the intervention than the classical technique; reduced duration of intervention, some authors Carrillo *et al* (2007) and Bar Zohar *et al* (2006), mention an average time of about 35 minutes. The main disadvantage is the need for general anesthesia. Currently, most studies try to impose the laparoscopic technique as Gold Standard in surgery of the patient with chronic kidney disease who must undergo peritoneal dialysis.

In the subsequent complications after placement of peritoneal dialysis catheter, common complications to any surgery and specific complications of peritoneal dialysis catheter insertion

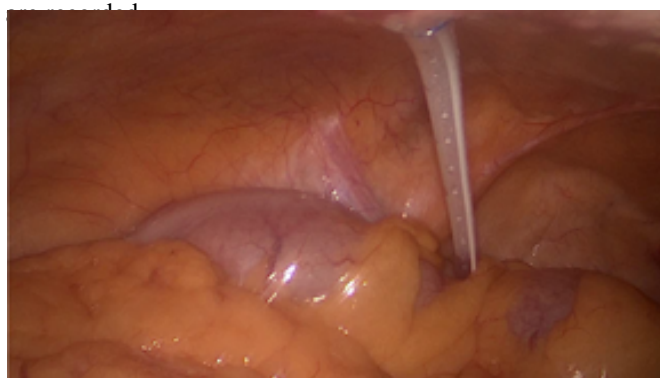

Figure 11. Correct mounting of the catheter

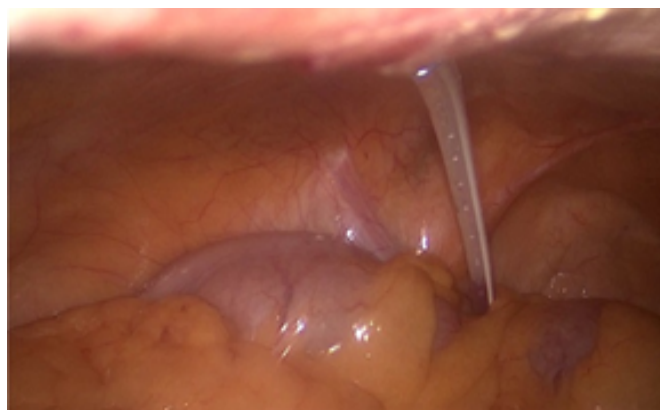

Figure 12. Correct mounting of the catheter

Among the common complications occurred early after surgery, we mention hemorrhage, perforation, incorrect placement of the catheter.

Hemorrhages are of two types, either at the level of the parietal wound (exteriorization breach or parietal tunnel) or intraperitoneal, by intraperitoneal organ damage. They are mainly associated with the classical technique, as they are greatly reduced within the laparoscopic technique. While intraperitoneal hemorrhages require immediate reoperation, hemorrhages of the parietal wound are predominantly treated in the conservative manner. They are particularly associated with the use of anticoagulants or the coagulation deficit which is particular to uremic patients. Compliance with a careful surgical technique and stopping the administration of oral anticoagulant treatment 24 hours before surgery can reduce the risk of these complications (Checherita et al 2009).

In our study, among the patients with catheter placement, we met a patient with minor postoperative bleeding in the parietal tunnel and this complication was treated conservatively and did not require re-intervention. The technique used in these patients was laparoscopy.

Organ perforation (gastrointestinal tract) is a serious complication requiring immediate reoperation and it is associated with the classical procedure. Direct visualization of the peritoneum in laparoscopic technique is thus the main advantage in reducing these complications.

Incorrect positioning of the catheter occurs predominantly in the classical technique, due to the lack of visualization of the bottom of Douglas bag. The consequence is catheter malfunctioning, which requires re-intervention, most often laparoscopic for repositioning.

In our study we have not seen cases of perforation or incorrect placement of the catheter.

Specific complications for catheter placement are mechanical and infectious complications.

Of mechanical complications (Bargman et al 2001), the most common are the mobilization of the catheter, with or without obstruction. In both cases, the solution is by reoperation, mainly of laparoscopic type, for disobliteration or repositioning. Catheter obstruction occurs through the great omentum wrapping around the catheter, which in turn promotes mobilization (Evangelos et al 2000; Pantea et al 2008; Soontrapornchai et al 2005), the catheter is inefficient and may even require its removal or resection of the omentum. In our study, we encountered two cases in the group of patients with peritoneal catheter placement. In the first case, catheter obstruction by omentum was solved when desobstruction and catheter repositioning were practiced, without requiring resection. In the latter case, catheter malfunctioning was observed immediately after the operation. Surgery was performed again and the catheter was removed.

In the case of the subcutaneous cuff exteriorization due to the mobilization, the attitude depends on the dialysis efficiency and the appearance of the breach or tunnel infection, as mechanical irritation given by the cuff on the breach increases the infection. In the case of a good catheter functioning, the portion of cuff that protrudes is resected and the evolution is controlled. Infection requires re-intervention and reconstruction of a new parietal tunnel at distance from the infected one, and changing the catheter is needed in some cases.

The occurrence of various fistulas (external peritoneal, peritoneo-intraparietal incomplete, peritoneo-pleural) is also a complication of peritoneal dialysis.

External peritoneal fistula, manifested by leakage of the discharge jet along the catheter, requires refraining from performing peritoneal dialysis for a while, which favors fistula closure. Joffe reported the use of parietal fibrin glues (Joffe et al 1993) to solve this complication (Carrillo et al 2007; Dalgiç et al 2002; Pantea et al 2008).

Peritoneo-intraparietal fistula is the only specific complication of laparoscopic technique. It is determined by the discharge jet penetration in parietal breaches that were made by trocar penetration. The complication is solved spontaneously in most cases (Chehab et al 2008; Ionescu et al 2008; Patrascu 2008). Peritoneo-pleural fistula occurs by dialysis fluid entering in the pleural cavity through anatomic orifices. It requires catheter removal and method's abandonment. Other authors recommend pleural talcage, injection of oxytetracycline or other pleural irritants, but the results are questionable (Mollica et al 2000; Patrascu 2008; Tang et al 2003).

In the group of patients with removed peritoneal catheters, we found a case with peritoneo-pleural fistula for which peritoneal dialysis was dropped, and the patient was undergoing hemodialysis.

Other complications, such as decubitus enteric fistula, hernias complicated with peritonitis and eventrations occur with much lower frequency.

Infectious complications (Bender et al 2006) are divided into two categories: catheter complications, which include infections of the exteriorization breach (Bernardini et al 2005), infections of the parietal tunnel, and peritonitis.

In the group of patients with catheter removal, the main determinant cause is represented by recidivating or recurrent peritonitis (16 cases), and infections of the catheter were not found in none of the studied groups (Bender et al 2006; Bernardini et al 2005; Piraino et al 2011).

Infectious complications are the main cause of morbidity and mortality in patients with chronic peritoneal dialysis (Duranay et al 2007; Odudu et al 2011; Kam-Tao et al 2010).

Infections of the exteriorization breach must be early diagnosed and treated to prevent their propagation in the tunnel or peritoneum. Achieving the objectives of the breach (its smallest diameter adapted to catheter size, and leaving it without being sutured) can decrease the frequency of this complication. If it occurs (Li et al 2011), it requires local and general topical antibiotic treatment. The dressing should be done with the utmost rigor. Tunnel infection generally occurs after breach infection. It requires catheter removal and placement of another catheter by making another tunnel at a distance from the infected one (Lui et al 2000, Kam-Tao et al 2010).

The most frequent bacteria involved are *Staphylococcus aureus* and *Pseudomonas aeruginosa*. Treatment is according to the antibiogram, but broad-spectrum antibiotic therapy is initiated until the results of the antibiogram are given. Preventing *Staphylococcus aureus* infection by administration of mupirocin has been very effective, too. Treatment should be continued until a normal aspect of the exteriorization breach, that is up to 2 weeks for *Staphylococcus aureus* and up to 3 weeks for *Pseudomonas* (Kam-Tao et al 2010).

Peritonitis is the most serious complication of peritoneal dialysis, being the main cause of ultrafiltration failure. They appear either after catheter infections, which are undiagnosed and untreated in an early stage (when they present the same microorganism), or independent of them. Antibiotic treatment should be given and, in case of peritoneal dialysis failure, catheter removal and abandonment of method should occur (Choi et al 2004; Duranay et al 2007; Jarvis et al 2010; Szeto et al 2009; Troidle et al 2005).

Encapsulating peritoneal sclerosis is a serious complication related to peritoneal dialysis. It can lead to intestinal obstruction and perforations. We encountered 3 cases of encapsulating peritoneal sclerosis in our study.

## Conclusions

The laparoscopic approach has many advantages. The major disadvantage is the need for general anesthesia. It is also followed by a smaller number of complications, in comparison with the celiotomic method.

Peritoneo-parietal fistula is the only complication related to the laparoscopic approach and has a very low incidence.

The method requires little time. The learning curve is reduced and it is a method that should be known by each surgeon.

The success of the method depends on the experience of the operating team, rather than on the type of catheter inserted.

Laparoscopic approach is likely to become the gold standard in peritoneal dialysis catheter placement.

## Acknowledgement

„This paper was co-financed from the European Social Fund, through the Sectorial Operational Programme Human Resources Development 2007-2013, project number POSDRU/159/1.5/S/138907 “Excellence in scientific interdisciplinary research, doctoral and postdoctoral, in the economic, social and medical fields -EXCELIS”, coordinator The Bucharest University of Economic Studies”.

## References:

- Akman S, Bakkaloglu SA, Ekim M, Sever I, Noyan A, Aksu N. Peritonitis rates and common microorganisms in continuous ambulatory peritoneal dialysis and automated peritoneal dialysis. *Pediatr Int* 2009;51:246-9.
- Bargman JM. Mechanical complications of peritoneal dialysis in handbook of dialysis by Daugirdas JT, Balke PG, Todd S, 3th edition Lippincott Williams and Wilkins 2001;399-404.
- Bar-Zohar D, Sagie B, Lubezky N, Blum M, Klausner J, Abu-Abeid S. Laparoscopic implantation of the Tenckhoff catheter for the treatment of end-stage renal failure and congestive heart failure: experience with the pelvic fixation technique. *Isr Med Assoc J* 2006;8:174.
- Bender FH, Bernardini J, Piraino B. Prevention of infectious complications in peritoneal dialysis: best demonstrated practices. *Kidney International* 2006;70:s44-s54.
- Bernardini J, Bender F, Florio T, Sloand J, Palmmontalbano L, Fried L, et al. Randomized double blinded trial of antibiotic exit site cream for the prevention of exit site infection in peritoneal dialysis patients. *J Am Soc Nephrol* 2005;16:539-45 .
- Carrillo SA, Ghersi MM, Unger SW. Laparoscopic-assisted peritoneal dialysis catheter placement: a microinvasive technique. *Surg Endosc* 2007;21:825.
- Checherita IA, David C, Ciocalteu A, Lascar I. Managementul medico-chirurgical la bolnavii renali cronici. *Chirurgia* 2009;104(5):525.
- Chehab B, Salyers W. Pneumoperitoneum complicating peritoneal dialysis catheter. *Kansas Journal of Medicine* 2008;56-57.
- Choi P, Nemati E, Banerjee A, Preston E, Levy J, Brown E. Peritoneal dialysis catheter removal for acute peritonitis: a retrospective analysis of factors associated with catheter removal and prolonged post-operative hospitalization. *Am J Kidney Dis* 2004;43:103-11.
- Crabtree JH, Burchette RJ. Effective use of laparoscopy for long-term peritoneal dialysis access. *Am J Surg* 2009;198:135-41.
- Crabtree JH, Fishman A. A laparoscopic approach under local anesthesia for peritoneal dialysis access. *Perit Dial Int* 2000;20:757.
- Cronen PW, Moss JP, Simpson T, Trao M, Cows L. Tenckhoff catheter placement: surgical aspects. *Am Surg* 1985;51:627.
- Dalgic A, Ersoy E, Anderson ME, Lewis J, Engin A, D'Alessandro AM. A novel minimally invasive technique for insertion of peritoneal dialysis catheter. *Surg Laparosc Endosc Percutan Tech* 2002;12:252.
- Duranay M, Kanbay M, Turgut F, Altay M, Akcay A. Comparison of incidence of peritonitis between peritoneal dialysis solution types. *Nephron Clin Pract* 2007;106:c57-60.
- Evangelos T, Philipos S, George G, Chrysoula T, George S, Michael P, Adamandia M. Laparoscopic placement of the Tenckhoff catheter for peritoneal dialysis. *Surg Laparosc Endosc Percutan Tech* 2000;10:218.
- Figueiredo A, Bak-Leong G, Jenkins S, Johnson D, Mactier R, Ramalakshmi S, et al. Clinical practice guidelines for peritoneal access. *Peritoneal Dialysis Int* 2010;30:424-429.
- Ionescu C, Ecobici M, Olaru D, Stanescu C, Lupescu I, Voiculescu M. Pneumoperitoneum - Rare Complication in End Stage Renal Disease Patient on Automated Peritoneal Dialysis. *Rom J Intern Med* 2008;46(4):351-355.
- Jarvis EM, Hawley CM, McDonald SP, Brown FG, Rosman JB, Wiggins KJ, et al. Predictors, treatment, and outcomes of non-pseudomonas gram-negative peritonitis. *Kidney Int* 2010;78:408-414.
- Joffe P. Peritoneal dialysis catheter leakage treated with fibrin glue. *Nephrol Dial Transplant* 1993;8:474-76 .
- Kam-Tao LP, Chun SC, Piraino B, Barnadini J, Figueiredo A, Gupta A, et al. Peritoneal dialysis-related infections recommendations: 2010 update. *Perit Dial Int* 2010;30:393-423.
- Li JR, Chen M, Yang CK, Shu KH, Ou YC, Ho HC, et al. A novel method of laparoscopy-assisted peritoneal dialysis catheter placement. *Surg Laparosc Endosc Percutan Tech* 2011;21:106-10.
- Lui SL, Li FK, Lo CY, Lo WK. Simultaneous removal and reinsertion of Tenckhoff catheter for the treatment of refractory exit-site infection. *Adv Perit Dial* 2000;16:195-7.
- Mollica A, Gerace G, De Napoli N. Recurrent hidrotorax in CAPD patients. *Perit dial int* 2000; 20(2):266.
- Mutter D, Marichal JF, Heibel F, Marescaux J, Hannedouche T. Laparoscopy: an alternative to surgery in patients treated with continuous ambulatory peritoneal dialysis. *Nephron* 1994;68:334.
- Odudu A, Wilkie M. Controversies in the management of infective complications of peritoneal dialysis. *Nephron Clin Pract* 2011;118:c301-8.
- ÖEünç G, Tuncer M, ÖEünç D, Yardimsever M, Ersoy F. Laparoscopic omental fixation technique vs. open surgical placement of peritoneal dialysis catheters. *Surg Endosc* 2003;17:1749.
- Pantea S, Luchian G, Pantea C, Lazar F, Bordsos D, Papurica M, et al. Plasarea cateterului Tenckhoff pentru dializa peritoneala prin abord laparoscopic. *Chirurgia* 2008;103(6):669-672.
- Patrascu T, Buga C. *Tratat de chirurgie, sub redactia Irinel Popescu* 2008; vol.VIII, part I B,1044-1056.

- Piraino B, Bernardini J, Brown E, Figueiredo A, Johnson D, Wai-Choong L, et al. ISPD position statement on reducing the risks of peritoneal dialysis - related infections. *Perit Dial Int* 2011;31:614-630.
- Popovich RP, Montcrief JF, Bomar JB, Pyle WK. The definition of a novel portable wearable equilibrium dialysis technique. *Trans Am Soc Artif Intern Organs* 1976;5:64.
- Rachandeep S, Madhukar M. An unusual complication of peritoneal dialysis catheter. *Adv in Perit Dial* 2009;25:96-98.
- Mital S, Fried LF, Piraino B. Bleeding complications associated with peritoneal dialysis catheter insertion. *Perit Dial Int* 2004;24:478-480.
- Soontrapornchai P, Simapatanapong T. Comparison of open and laparoscopic secure placement of peritoneal dialysis catheters. *Surg Endosc* 2005;19:137.
- Szeto CC, Kwan BC, Chow KM, Law MC, Pang WF, Chung KY et al. Recurrent and relapsing peritonitis: causative organism and response to treatment. *Am J Kidney Dis* 2009;54:702-10.
- Tang S, Chui WH, Li FK, Chau WS, Ho YW, Chan TM, Lai KN. Video-assisted thoracoscopic talc pleurodesis is effective for maintenance of peritoneal dialysis in acute hydrothorax complicating peritoneal dialysis. *Nephrol Dial Transplant* 2003;18:804-08.
- Troidle L, Gorban-Brennan N, Finkelstein FO. Outcome of patients on chronic peritoneal dialysis undergoing peritoneal catheter removal because of peritonitis. *Adv Perit Dial* 2005;21:98-101.
- Wang JY, Hsieh JS, Chen FM, Chuan CH, Chan HM, Huang TJ. Secure placement of continuous ambulatory peritoneal dialysis catheters under laparoscopic assistance. *Am Surg* 1999;65:247.
- Wankowitz Z. Peritoneal dialysis-the role in the integrated renal care, pitfalls and benefits of therapy. *Adv Clin Exp Med* 2003;12(2):243-249.

## Authors

- Anca Manta, Department of General Surgery, Clinical Hospital of Nephrology “Dr. Carol Davila”, Bucuresti, Romania, EU, email:
- Cristian I. M. Iorga, Clinical Hospital of Nephrology “Dr. Carol Davila”, Bucuresti, Romania, EU, email: cris.iorga@yahoo.com
- Victor Strimbu, Clinical Hospital of Nephrology “Dr. Carol Davila”, Bucuresti, Romania, EU, email: drstrimbu@gmail.com
- Florian Popa, Department of General Surgery, Clinical Emergency Hospital “Sf. Pantelimon” Bucuresti, Romania, EU

<b>Citation</b>	Manta A, Iorga CIM, Strimbu V, Popa F. The role of laparoscopic approach in reducing complications of peritoneal dialysis. <i>HVM Bioflux</i> 2014;6(4):203-209.
<b>Editor</b>	Ștefan C. Vesa
<b>Received</b>	22 October 2014
<b>Accepted</b>	6 November 2014
<b>Published Online</b>	22 November 2014
<b>Funding</b>	European Social Fund, through the Sectorial Operational Programme Human Resources Development 2007-2013, project number POSDRU/159/1.5/S/138907
<b>Conflicts/Competing Interests</b>	None reported